

Original paper

A comparative study of treatment of fistula in ano - fistulectomy versus Seton

Litake Manjusha M., Sudheer K.

Department of surgery, B J Government Medical College, Pune

Corresponding author: Sudheer K.

ABSTRACT:

OBJECTIVES:: To do Comparative study of “Treatment of fistula in Ano – fistulectomy versus seton” with respect to operative time, post operative analgesia requirement, post operative hospital stay, wound Healing time, return to normal activities, study the incidence of postoperative complications like pain, infections , bleeding, incontinence and recurrence in a tertiary care centre.

MATERIAL AND METHOD: This is randomised, comparative, prospective study of 40 cases of fistula in ano, presenting at Surgical OPD of tertiary care centre. Out of which 20 cases treated by fistulectomy and 20 cases by seton by random selection method during period of DEC 2009 to JUNE 2011.

RESULT: The maximum number of cases of fistula in ano is found in the age group of 31-40 years. Male: Female was 5.66:1. Fistulectomy as compared to Seton treated patients, required more mean operative time, post operative analgesia and time required to return to normal routine activity due to post operative open raw wound in perianal region. Most of the patients treated with seton technique are satisfied with procedure as there is minimal post operative complications, no incontinence & recurrence within 6 months of follow up and it doesn't leave any open wound behind. Some patients are uncomfortable due to feeling of foreign body sensation in seton treated group. Incidence of Incontinence is low in both groups.

INTRODUCTION:

Fistula is an abnormal connection between two hollow organs or between hollow organ and the skin lined by epithelial tissue. In cases of fistula in ano, it is a track that connects deeply the anal canal or rectum to the skin around the anus. The primary opening is deep in the anal canal or rectum and the superficial openings, which may be multiple, are around the perianal skin. Being a common surgical condition, fistula in ano most commonly follows a anorectal sepsis⁽¹⁾, puts a surgeon in challenging situation to decide about best option for the patient and to satisfy the patient. The main principles of management of anal fistula are closure of internal opening of fistula tract, drainage of infection or necrotic tissue, and eradication of fistulous tract with preservation of sphincter function⁽²⁾. Studies have revealed that high fistulae have low incidence. Low fistulae are the commonest anal fistulae and can be treated easily by conventional laying-open technique. High fistula-in-ano are difficult to treat since the conventional laying-open will lead to division of most of the anal sphincter muscles resulting in incontinence. To achieve the objective in high anal fistulae, different surgical techniques have been described in literature from time to time. These include Park's fistulotomy, insertion of a seton, two-stage-fistulotomy, primary fistulectomy with occlusion of the internal ostium, fistulotomy with primary repair of the sphincter, endorectal advancement flaps , anocutaneous advancement flap, repair of fistula using fibrin adhesive glue and re-routing the fistula⁽⁶⁾.

Description of seton dates back to age of Sushruta, in his sushruta samhita in which for the first time he used chemical seton, before which Hippocrates used horse hair as a seton. This study is unique in that matter, as there is no study in the literature comparing fistulectomy with seton. Seton is any string-like material, medicated or non medicated which when tied through the fistula tract causes an inflammatory reaction which stimulates fibrosis that fixes and prevents retraction of the sphincter continuity when it is divided. In this way, it maintains sphincter continuity during cutting process⁽¹³⁾. Different types of setons are used for this purpose like silastic tube, silk, linen, braided silk, rubber band, braided polyester, vascular loop, polypropylene, nylon, cable tie, and so forth⁽¹³⁾. The reported incontinence and recurrence rate ranges from 0% to 62%⁽¹³⁾ and from 0% to 16%⁽¹³⁾, respectively, with different materials used as seton. There are 4 different seton techniques described namely two staged fistulectomy with seton, cutting seton, short term drainage with seton and long term drainage with seton⁽¹⁹⁾.

MATERIALS AND METHODS:

This is a randomised, comparative, prospective study of 40 cases of fistula in ano, presenting at surgical opd of tertiary care centre. Out of which, 20 cases are treated by fistulectomy and 20 by seton, by random selection method, during period of DEC 2009 to JUNE 2011.

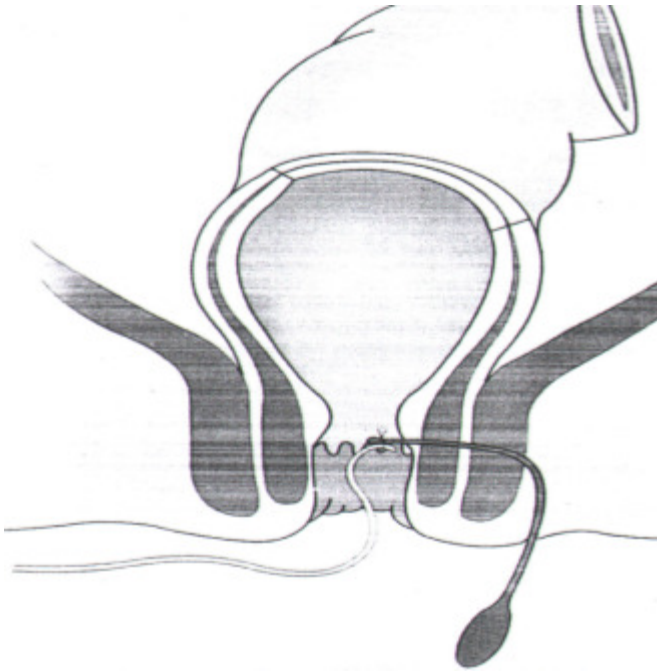
Clinical history and Clinical examination including per rectal and proctoscopic examination was done in all the patients. All the patients were processed by routine investigations, chest X-ray etc., prior to surgery. Pus culture sensitivity and Fistulogram was done in all cases. C.T. Scan and M.R fistulogram as per requirement.

All patients, of age 20-60 yr with fistula in ano attending surgical OPD between Dec 2009 to Dec 2011 were included in the study. Patient with other anorectal diseases, Ca rectum& IBD, less than 20 yr and more than 60 yr, other co-morbid condition like CCF, uncontrolled DM, and immuno-compromised status were excluded.

TECHNIQUE OF FISTULECTOMY

After written informed consent of patient and relative, patient was taken into the operation theatre. Under spinal anaesthesia patient was put in lithotomy position. The parts were painted using 10% betadine and draped. The site of the external opening of the fistula and its distance from the anal verge was recorded. Then the position of the internal opening was determined in relation to anal verge and anorectal ring. With the help of malleable probe, probing of the fistulous tract was carried out from external opening to determine the extent and direction of tract and its termination. Its other end was then brought through the anus and area was infiltrated with 2% lignocaine solution. Then by applying a gentle traction on the U-shaped angulated probe with the left hand, and cutting close to the probe on either side, the whole of the fistulous tract was excised out and sent to HPR examination. Hemostasis achieved, the raw area was then packed with wet gauze.

TECHNIQUE OF SETON INSERTION



After written informed consent of patient and relative patient was taken into the operation theatre. Under spinal anaesthesia patient was put in lithotomy position. The parts were painted using 10% betadine and draped.

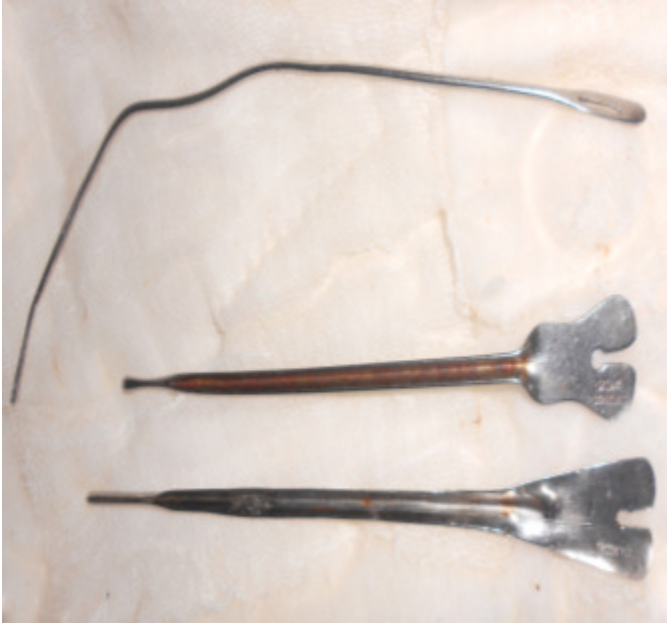The site of the external opening of the fistula and its distance from the anal verge was recorded. Then the position of the internal opening was determined in relation to anal verge and anorectal ring. With the help of malleable probe, probing of the fistulous tract was carried out from external opening to determine the extent and direction of tract and its termination. Silk 1-0 suture were threaded through the internal opening using fistula probe. A Roders knot was made. The patient was instructed to pull the tail of the cutting seton, till he felt the pain which was not tolerable on a daily basis one week after the procedure.

Repeated examinations were carried out at two week intervals. At each visit, the position of the seton was assessed. The data of previous anal operations, history of incontinence before and after seton treatment, wound healing, and recurrence of anal fistula was recorded.

Methods to identify the internal opening:

- a. Passage of probe from external opening into internal opening.
- b. Injection of dye through the external opening and following the tract.
- c. By following the granulation tissue of the tract.
- d. Noting puckering of the anal canal, when traction is applied to external opening.

This is a very important step as it minimizes the recurrence.



FISTULA PROBES FOR SETON INSERTION

DISCUSSION:

Fistula in ano is very common surgical problem, posing great challenge in treatment. There are many treatment available at present namely fistulectomy, fistulotomy, LIFT, seton technique. As each procedure is associated with its own complication seton technique appears attractive to patients with less complication, lesser duration of surgery. Patient satisfaction depends on factors like postoperative hospital stay, postoperative pain and bleeding, return to routine activity, wound healing time, interference with the anal continence and most importantly the recurrence of the disease. There are very limited number of studies has investigated routine use of seton placement for the treatment of anal fistulas. This study is to compare the fistulectomy versus seton technique. The principles of management of fistula in ano are drainage of infection and eradication of fistulous tract with preservation of sphincter function. A seton is a thread or thread like foreign material, that is placed in the fistula tract. The common material used are sutures, rubber, wire and medicated thread. The function of the seton is to provide drainage and gradually transect the muscles by pressure necrosis, the fibrosis that follows fix and prevents retraction of sphincter and anal incontinence.

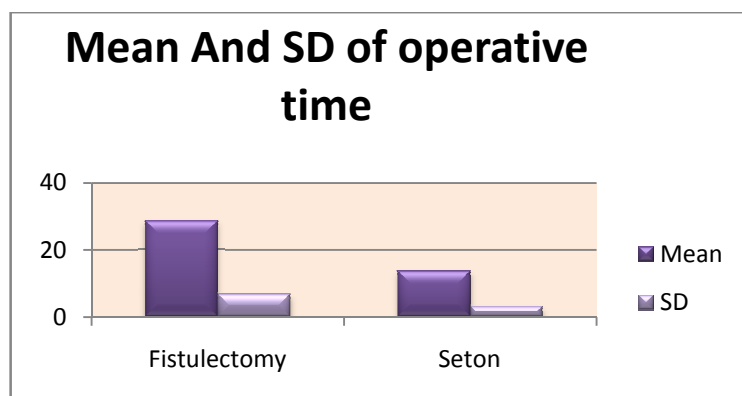
In this study, total 40 cases studied. The maximum number of cases of fistula in ano are found in the age group of 31-40 years^(5,7) with a Male: Female ratio of 5.66:1, which is comparable with other similar studies Quazi et al and Yasmin Bhatti et al.

Perianal discharge being the most common presenting symptom as found in R.N Mangul et al⁽⁸⁾

Internal opening was present anteriorly in 20% and posteriorly in 80% of the patients^(7,9,18). We had patients of varied no of internal opening; single opening in 87.5% double opening 10% in multiple opening in 2.5%⁽⁷⁾.

Sr. No	Study	Anterior	Posterior
1.	M K Mahajan et al (2007) ⁽⁹⁾	32%	68%
2.	Paiboon jivanpaisarnpong(2009) ⁽²⁰⁾	33.33%	66.66%
3.	Yasmeen Bhatti et al(2011) ⁽⁷⁾	33.33%	66.66%
4.	Present study	20%(8/40)	80%(32/40)

Operating time was significantly low in seton group as compared with that of fistulectomy group.



Average healing time in patients who underwent fistulectomy was 47.5 days^(7,12) and in seton group 30 days^(5,9). Post operative stay for seton group was 6.9 days and fistulectomy patients was 13 days⁽⁹⁾.

Sr. No.	Study(Seton)	Average healing time
1.	G. Rose et al(2006)	21days
2.	Misra and kapur(1988) ⁽¹⁰⁾	25 days
3.	A.R. Qazi et al(2008) ⁽⁵⁾	40 days
4.	Present study	30days

Sr. No.	Study (Fistulectomy)	Average healing time
1.	Yasmeen Bhatti et al(2011) ⁽⁷⁾	35 days
2.	Kronborg et al(1985) ⁽¹²⁾	41 days
4.	Present study	47.5 days

Duration of hospital stay was more in fistulectomy group because of open peri-anal wound. Post operative pain was significantly high (45%) in patients with fistulectomy as compared to those with seton which is found to be similar in other studies^(5,7).

Post operative infection was about 20% in seton group which was more compared to fistulectomy group (5%) mostly because in our study as we had complete excision if fistulous tract in all the patients and there is no data available regarding infection rate in fistulectomy in the literature.

Sr. No.	Study	Post operative infection
1.	M. Misra et al (1988) ⁽⁵⁹⁾	7(13.2%)
2.	Present study	4/20 (20%)

Post operative bleeding was more among fistulectomy group about 15% compared to 5% in seton group because seton technique uses technique of pressure technique which is a slow and gradual process.

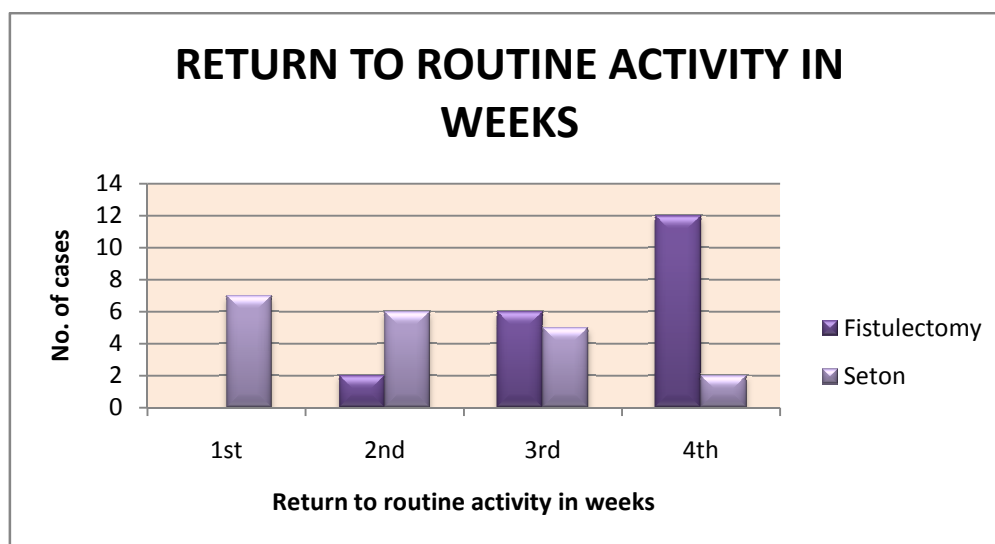
The major worry for the patient and the surgeon in fistulectomy is incontinence which was about 10%, which was a minor incontinence only to flatus in fistulectomy group and there was absolutely zero number of incontinence with seton group, supporting the results of various other studies^(11,14-17).

Sr. No.	Study	recurrence rate	Incontinence
1.	Sagap I et al(2006) ⁽²¹⁾	4%	Upto 45%
2.	Yasmeen Bhatti et al(2011) ⁽⁷⁾	Nil	Nil
3.	Present study	Nil	10%(Minor)

From this study, we have also observed that fistulectomy patients as compared to seton, required more mean operative time, post operative analgesia and healing time. More importantly there is absolutely no incontinence in seton group.

Most of the patient in seton group returned to their activities in their first week, where as fistulectomy group took more time because of open wound.

Return to routine activity in weeks	Fistulectomy		Seton	
	No of cases	Percentage	No of cases	Percentage
1 st	0	0	7	45%
2 nd	2	10%	6	30%
3 rd	6	30%	5	25%
4 th	12	60%	2	10%



CONCLUSION:

From our study of “Treatment of fistula in Ano – fistulectomy versus seton” in low variety of fistula in ano, we conclude that:

- 1) As compared to the seton technique, fistulectomy is more time consuming.
- 2) Fistulectomy require more post operative analgesia for pain management.
- 3) Post operative hospital stay is less in the patient treated with seton as compared to fistulectomy group.
- 4) Wound healing time is less in patients treated with seton as compared to the fistulectomy.
- 5) As compared to the fistulectomy, seton treated patient’s return to normal activities earlier.
- 6) Seton requires multiple setting of tightening of thread which is done on O.P.D. ybasis.
- 7) Histopathological diagnosis is possible in Fistulectomy as excised fistula tract can be sent for histopathological examination which is not possible with Seton treatment.
- 8) Post operative complication like pain, bleeding and urinary retention are more in fistulectomy patients as compared to the seton treated patients.

- 9) Seton treated patient are more comfortable than fistulectomy.
- 10) Incontinence and recurrence are not observed with seton treatment in our study.

BIBLIOGRAPHY:

- 1) Henrichsen S, Christiansen J., Incidence of fistula-in-ano complicating anorectal sepsis: a prospective study, *Br J Surg*. 1986 May;73(5):371-2.
- 2) Mc Courtney J.S, Finlay I.G. Setons in the surgical management of fistula in ano. *British Journal Surgery* 1995 ;82:448-52.
- 3) Seow-Choen F, Nicholls R.J. Anal fistula. *Br J Surg* 1992; 79: 197-205.
- 4) Marks CG, Ritchie JK. Anal fistulas at St Mark's Hospital. *Br J Surg* 1977; 64: 84-91
- 5) Abdul Razaque Qazi, Jan Muhammad Memon, Roshan Ali Solangi, Syed Qaiser Hussain Nauqvi. Outcome analysis of partial fistulotomy with seton. *Pakistan Journal of Surgery* 2008; 24:15-8.
- 6) Gurer A, Ozlem N, Gokakin AK, Ozdogan M, Kulacoglu H, Aydin R. A novel material in seton treatment of fistula-in-ano. *American Journal of surgery* 2007; 193:794-6.
- 7) Yasmeen Bhatti, Saira Fatima, G.S.Shaikh, Shahida Shaikh. Fistulotomy versus fistulectomy in the treatment of low fistula in ano. *Rawal Medical Journal* 2011; 36:1-8.
- 8) R.N. Mangual, D.N. Tudu, S.P. Pattaik, K.P. Prusty. The sphincter preserving perianal fistulectomy: A better alternative. *Indian Journal of Surgery* 2004;66:31-35.
- 9) M. K. Mahajan, V Gupta, S.R.Anand. Evolution of fustulectomy and primary skin grafting in low fistula in ano. *J.K. science* 2007; 9:68-71.
- 10) M.C. Misra, B.M. Kapur. A new non operative approach to fistula in ano. *British Journal of Surgery* 1988; 75:1093-4.
- 11) A.Theerapol, B.Y.J.So, S.S.Ngoi. Routine use of setons for the treatment of anal fistulae. *Singapore Medicine Journal* 2002; 43:305-7.
- 12) Kronborg O. To lay open or excise a fistula-in-ano: a randomized trial. *British Journal Surgery* 1985 ; 72:970.
- 13) M.Vial, D. Parés, M. Pera, and L. Grande, "Faecal incontinence after seton treatment for anal fistulae with and without surgical division of internal anal sphincter: a systematic review," *Colorectal Disease*, vol. 12, no. 3, pp. 172–178, 2010.
- 14) Deshpande PJ, Sharma KR, Sharma SK et al. Ambulatory treatment of fistulo-in-ano: results in 400 cases. *Indian JSurg*1975; 37: 85–9.
- 15) Fasth SB, Nordgren S, Hultén L. Clinical course and management of suprasphincteric and extrasphincteric fistula-in-ano. *ActaChirScand*1990; 156: 397–402.
- 16) Gonzalez-Ruiz C, Kaiser AM, Vukasin P et al. Intraoperative physical diagnosis in the management of anal fistula. *AmSurg*2006; 72: 11–5.
- 17) Hamel CT, Marti WR, Oertli D. Simplified placement and management of cutting setons in the treatment of transsphincteric anal fistula: technical note. *Int J Colorectal Dis*2004; 19: 354–6.
- 18) Siripong Sirikurnpiboon, Burin Awapittaya, and Paiboon Jivapaisarnpong, Ligation of intersphincteric fistula tract and its modification: Results from treatment of complex fistula, *World J Gastrointest Surg*. 2013 Apr 27; 5(4): 123–128.
- 19) William H. Isbister. *Fistula-in-ano*. *Aust. N.Z. J. Surg* 1999;69:768–9.
- 20) Paiboon Jivapaisarnpong. Core out fistulectomy, Anal sphincter reconstruction and primary repair of internal opening in the treatment of complex anal fistula. *J Med Assoc Thai* 2009;92:638-42.
- 21) Ismail Sagap, F.H. Remzi. Controversies in the treatment of common anal problems. *World J Gastroenterol* 2006;12:3146-54.